

## Ocular Cystinosis in a routine Ophthalmologic Evaluation.

Jorge Alberto Amorim Oliveira, Thales Antonio Abra de Paula, Rodrigo Jorge Amorim, Mariana Xavier Araújo de Oliveira, Juliane de Carvalho Rocha Moura, Mateus Conciani, Thássia Kauany Feitosa da Silva

Medical residency in: Radiology and diagnostic imaging Registration number: Fellow of: UDI HOSPITAL, UDI, Brazil.

## Abstract

Cystinosis is a rare autosomal recessive metabolic disease. It occurs due to a chromosomal mutation that allows the accumulation of this amino acid in lysosomes. Cystine can form crystals in various tissues such as the kidneys, pancreas, thyroid, testicles, bone marrow, brain, eye, and muscles. In the eyes, crystals can cause deposits on the cornea and conjunctiva. In the cornea, deposits occur in the periphery and anterior stroma. As the disease progresses, the crystals move centripetally and posteriorly. Oral and topical treatments with cysteamine have been described. The ophthalmologic solution of cysteamine 0.55% used continuously every 2 hours has shown good results. The objective of this work was to demonstrate the clinical case of a patient in a routine consultation, with findings of cystine crystals in the cornea, as well as a corneal densitometry exam with alterations suggestive of cystinosis. In view of this, we emphasize the importance of the ophthalmological examination for the diagnosis of the case.

**Keywords:** Cystinosis, Cornea, Crystals, Densitometry, Kidney disease

## INTRODUCTION

Cystinosis is a rare autosomal recessive metabolic disease, with an incidence ranging from 1:100,000 to 1:200,000. It occurs by chromosomal mutation, in which a defect in the active transport of cystine across the lysosomal membrane allows the accumulation of this amino acid in lysosomes.<sup>1</sup> As a result, cystine can form crystals in various tissues such as the kidneys, pancreas, thyroid, testicles, bone marrow, brain, eye, and muscles<sup>2</sup>.

Three phenotypic forms of cystinosis are described: Infantile nephropathic form - more common and more severe, usually associated with Fanconi syndrome and need for kidney transplantation in the first decade of life; Juvenile nephropathic form - later onset and less severe; Non-nephropathic form - more currently called ocular cystinosis, benign in character, usually with isolated, asymptomatic ophthalmologic findings, and may present from adolescence to the fifth decade of life<sup>3</sup>.

The ocular symptoms of cystinosis result from the deposition of cystine crystals. The crystals are deposited mainly on the cornea and conjunctiva. In the cornea, the deposits are located in the periphery and anterior stroma, and as the disease progresses, the crystals move centripetally posteriorly<sup>2</sup>. The deposits may also affect the corneal epithelium, which may be related to the foreign body sensation reported by some patients<sup>6</sup>. The deposits become increasingly dense without proper treatment, causing photophobia and worsening of

visual acuity<sup>3,5</sup>.

Cystinosis may present with other ocular manifestations such as retinitis pigmentosa, macula ridge deposits, posterior syncytia, glaucoma, and hemorrhagic retinopathy. In all cases, there is a risk of worsening visual acuity<sup>1</sup>. Ocular complications may be associated with the progression of the systemic disease, so regular and multidisciplinary follow-up is important.

Treatment should be done with oral and topical cysteamine. The ocular treatment can be done with cysteamine solution 0.55% (used continuously 02/02h). Currently, the use of this solution has shown good results, and therefore it should be prescribed in all cases of cystinosis with ocular involvement<sup>1</sup>.

## CLINICAL CASE

A 26-year-old female patient went for a routine ophthalmological evaluation, wishing to change her glasses. In the refractometry exam she presented a visual acuity of 20/20, with the following correction OD: - 0.50 DE; OE: -1.25 -0.25 90°. The biomicroscopic examination observed in both eyes (BE): mild blepharitis, diffuse stromal crystal deposits throughout the corneal stroma (Figures 1,2) Retinal mapping without BO alterations. Complementary exam: corneal densitometry, performed by pentacam, showing higher density mainly in the anterior third of the cornea (up to 120 microns) BE. The graph also shows decreasing density in the anterior to posterior direction in relation to corneal thickness.(Figures 3,4)

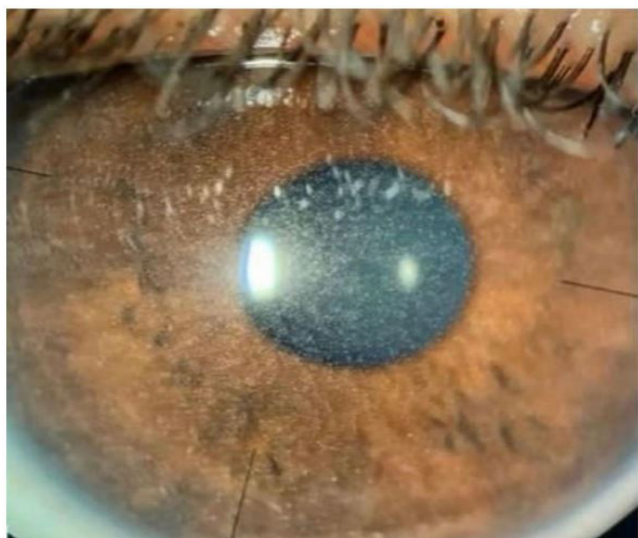
About 7 years ago the patient had constitutional symptoms with weight loss and anorexia, reason why she sought medical help where she was found to have difficult to control anemia and deteriorated renal function. At the same time she underwent dialysis for 4 months and was put on the kidney transplant waiting list. One year after the onset of the condition, she underwent a kidney transplant, with her sister as a compatible donor. No renal biopsy or further investigations about the type of pathology were performed.

After ophthalmological examination and oriented to seek a new evaluation with the nephrologist to report ophthalmological findings compatible with cystinosis.

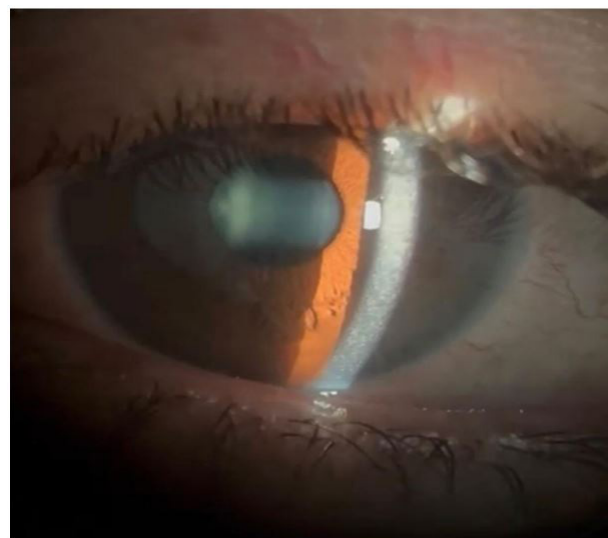The patient is currently awaiting an appointment for further clinical evaluation because she has lost the follow-up with the nephrologist

**\*Corresponding Author:** \*Jorge Alberto Amorim Oliveira, Medical residency in: Radiology and diagnostic imaging Registration number: Fellow of: UDI HOSPITAL, UDI, Brazil.

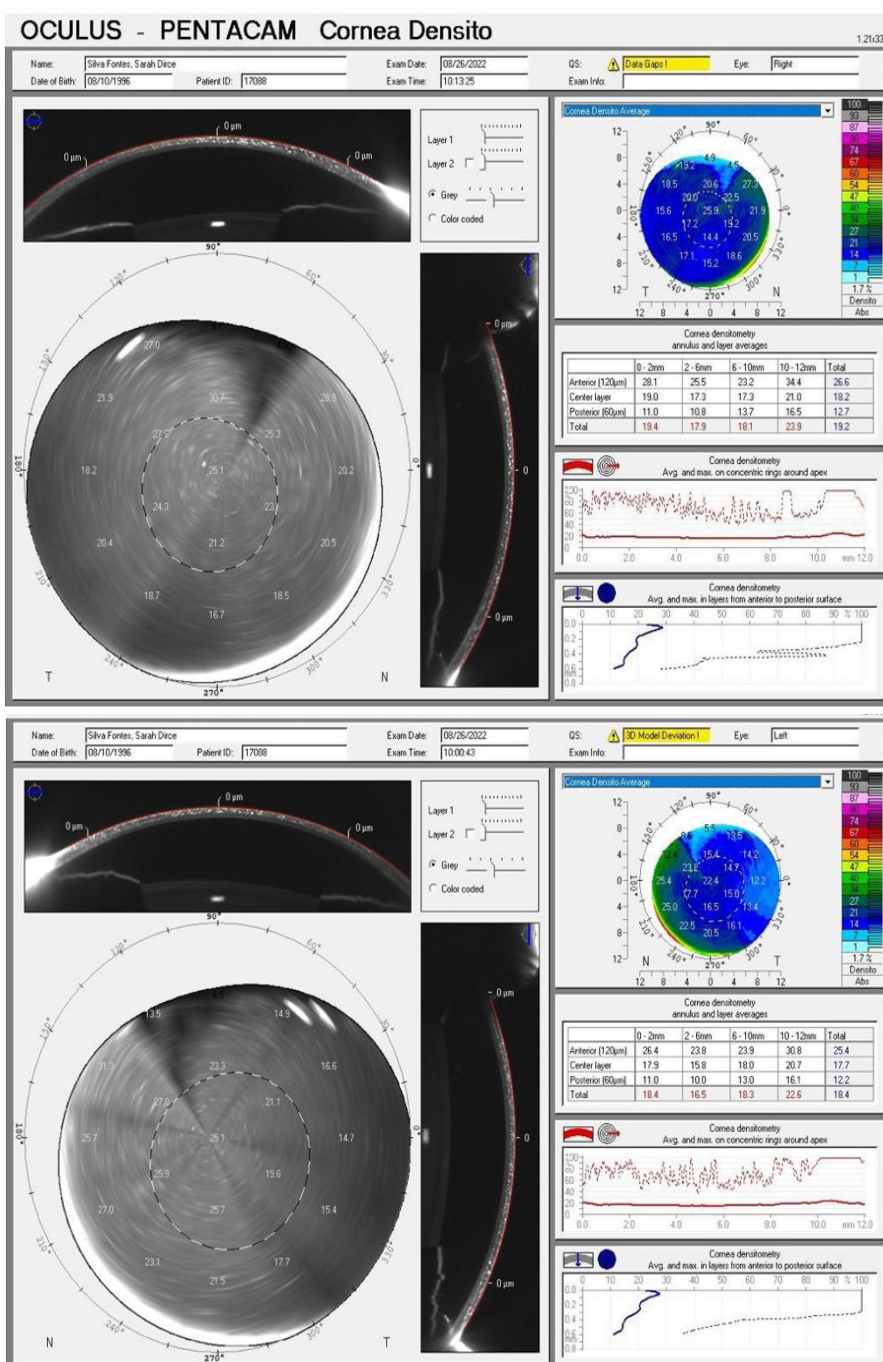
**Citation:** \*Jorge Alberto Amorim Oliveira. Ocular Cystinosis in a routine Ophthalmologic Evaluation.. Jourl of Clin Stud and Med Imag, Cas Rep. 2023; 1(1): 1002.



**Figure 1 :** Biomicroscopy showing crystal deposits on the cornea



**Figure 2 :** Optical section demonstrating crystals in the corneal stroma



**Figures 3,4:** Corneal desintometry of the right and left eyes showing increased density in the anterior third (120 µm), and decreasing density in the anterior to posterior direction.

who was following her case.

## DISCUSSION

Cystinosis is a rare disease characterized by the accumulation of cystine crystals in various tissues of the body. Its spectrum ranges from milder forms with only ocular involvement to severe forms involving several organs, including the kidney.

The patient in question went for a routine consultation where she was asymptomatic. On ophthalmologic examination, the anterior biomicroscopy is compatible with a diagnosis of ocular cystinosis. In addition, she had corneal densitometry showing changes due to crystal deposits.

The patient's past history is relevant and corroborates with the ophthalmological findings. The patient had severe kidney disease, requiring kidney transplantation, but the disease was not elucidated. Therefore, the ophthalmological examination was fundamental for the diagnosis of the case.

## Reference

1. Diógenes M.B., et al. Cistinose ocular: um relato que enaltece a importância do tratamento tópico nos sintomas oculares. Fortaleza, CE. eOftalmo. 2020;6(2):46-9.
2. Shams, F., Livingstone, I., Oladiwura, D., & Ramaesh, K. (2014). Treatment of corneal cystine crystal accumulation in patients with cystinosis. *Clinical Ophthalmology*, 8, 2077-2084. Acesso em 20 de 2 de 2023, disponível em <https://ncbi.nlm.nih.gov/pubmed/25336909>
3. Bunya VY, et al. Cystinosis. Masako Chen, MD on June 30, 2022.
4. Victor G, et al. Microscopia confocal in vivo na cistinose - Relato de caso. São Paulo (SP). *Arq Bras Oftalmol* 2004; 67:553-7.
5. Vaisbich MH, et al. Abordagem multi (nnj) (S, et al.) (Shams, Livingstone, Oladiwura, & Ramaesh, 2014)disciplinar para pacientes com cistinose nefropática: modelo para atendimento em uma doença renal rara e crônica. São Paulo, SP, Brasil. *Braz. J. Nephrol. (J. Bras. Nefrol.)* 2019;41(1):131-141
6. Liang H, Baudouin C, Hassani RTJ, Brignole-Baudouin F, Labbe A. Photophobia and corneal crystal density in nephropathic cystinosis: an in vivo confocal microscopy and anterior-segment optical coherence tomography study. *Invest Ophthalmol Vis Sci*. 2015;56(5):3218-25